

HELMINTHS:

TAENIA SOLIUM (PORK
TAPEWORM),

PREPARED BY: MR. BORUN KATHAR
ASSISTANT PROFESSOR
PDUAM, DALGAON
DARRANG, ASSAM.

HELMINTHS:

The helminthic parasites are multicellular (Metazoa) bilaterally symmetrical animals having three germ layers (tripoblastic metazoa) and belong to the kingdom Metazoa.

Helminths, which occur as parasite in human belongs to two phyla:

1. Phylum Platyhelminthes (Flatworms): It includes two classes:

a) Class: Cestoda (Tapeworm)

b) Class: Trematoda (flukes or digeneans)

2. Phylum Nematelminthes: it includes class Nematoda and two sub-classes:

a) Subclass: Adenophorea (Aphasmida)

b) Subclass: Secernentea (Phasmidia)

Table: Difference between Cestodes, Trematodes, and Nematodes.

Morphology	Cestodes	Trematodes	Nematodes
Shape	Tape-like, segmented	Leaf-like, unsegmented	Elongated, cylindrical, unsegmented
Head end	Suckers present; some have attached hooks. Possess scolex, neck and proglottids.	Suckers are present, but no hooks	Hooks and suckers are absent. Well-developed buccal capsules with teeth or cutting plates are seen in some species.
Alimentary canal	Absent	Present but incomplete, no anus	Complete with an anus.
Body cavity	Absent, but inside is filled with spongy, undifferentiated mesenchymatous cells, in the midst of which lie the viscera.	Same as cestodes	Present and known as pseudocoel. Viscera remains suspended in the pseudocoel
Sex	Not separate: Hermaphrodite (monoecious)	Not separate: Hermaphrodite (monoecious) except Schistosomes separate (diecious)	separate (diecious)
Life cycle	Requires two hosts except Hymenolepis (one host) and Diphyllobothrium (three hosts)	Requires three hosts except Schistosomes (two hosts)	Requires one host except filarial worms (two hosts) and Dracunculus (two hosts)

Cestodes are flat, parasitic, hermaphroditic tapeworms with complex life cycles that infect animals, including humans. Although there are multiple species of cestodes, three particular species cause human disease: *Taenia solium* (pork tapeworm), *Taenia saginata* (beef tapeworm), and *Diphyllobothrium* (fish tapeworm).

There are two types of infections that can develop depending on the route of infection. The first type is caused by ingesting the eggs from an adult worm (expelled in animal or human feces) which results in developing cysticerci (larval stage) within the animal or human tissues. This is known as cysticercosis. If these cysticerci develop in the central nervous system, this is called neurocysticercosis.

The **second type** is due to ingesting the cysticerci themselves, from poorly cooked infected meat, which results in the growth and infestation of the adult tapeworm within the gastrointestinal tract. The infection with the adult tapeworm is called **taeniasis** if infected by the *Taenia* family or **diphyllobothriasis** if infected by *Diphyllobothrium*

These tapeworm infections have significant human and veterinary disease implications as well as economic effects.[1][2] Neurocysticercosis is an important cause of **seizures** and accounts for approximately **30% of all epilepsy cases** in most developing countries

***Taenia solium*, The Pork Tapeworm**

Structure

The scolex of *T solium* differs from that of *T saginata* in possessing an anterior circle of sharply spined hooks arranged in a double row. These are under muscular control and work with the four suckers to adhere to the gut wall.













	<i>Taenia solium</i>	<i>Taenia saginata</i>	<i>Hymenolepis nana</i>	<i>Hymenolepis diminuta</i>	<i>Diphyllobothrium latum</i>	<i>Echinococcus granulosus</i>
Heads						
	4 suckers 2 rows of hooks	4 suckers No hooks	4 suckers single row of 20-30 hooks	4 suckers No hooks	2 Suctorial grooves or bothria, no suckers, No hooks	4 suckers 2 rows of hooks
Proglottids						
	Longer than broad 7-12 uterine branches on each side	Longer than broad 15-30 uterine branches on each side	Broader than long	Broader than long	Broader than long Uterus coiled	Longer than broad

Fig. 2: Differences between heads and proglottids of various Cestodes

As described above, gravid segments of *T. solium* can be distinguished from those of *T. saginata* by the number of outpocketing branches of the uterus. The adult worm is usually 3 to 5 m long. Gravid segments tend to be less muscular and more square than those of *T. saginata*

LIFE CYCLE

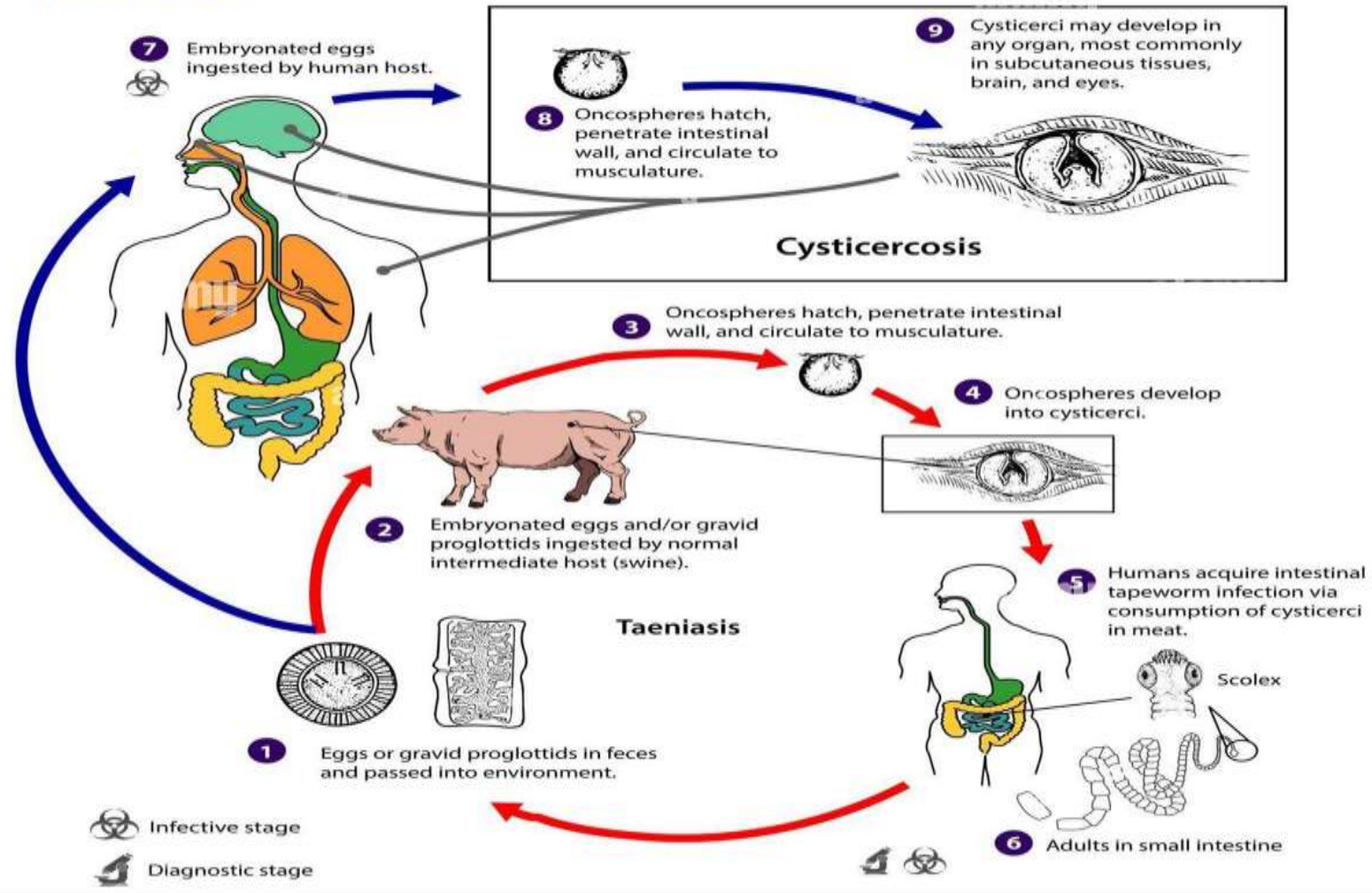
The life cycle of *T. solium* is similar to that of *T. saginata* except that the pig is the principal intermediate host. Because the gravid segments are less motile than those of *T. saginata*, they are usually eliminated in the fecal matter and remain in the fecal bolus (which increases the chance of infecting pigs, which are coprophagous).

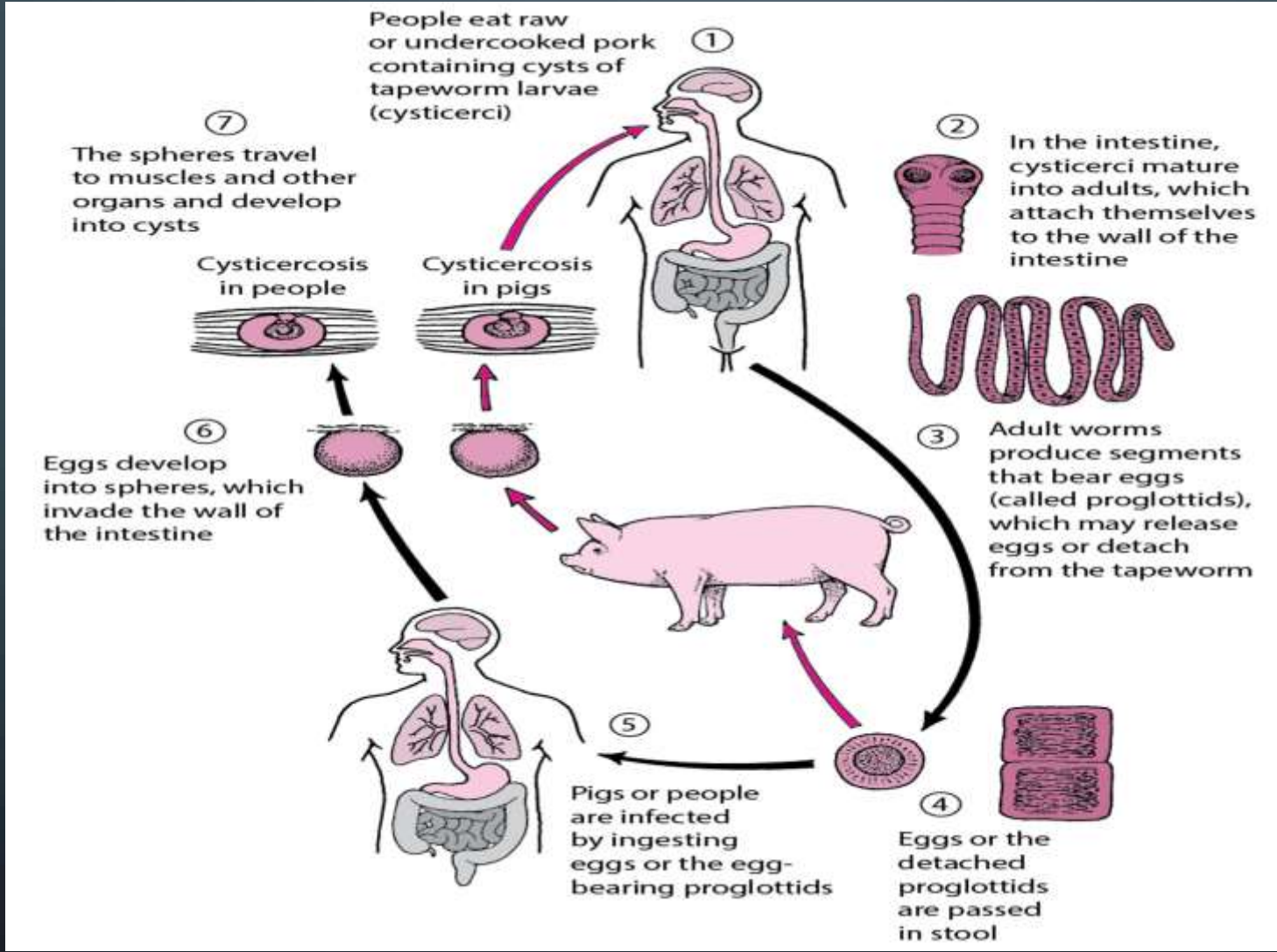
The life cycle of *T solium*

Definitive host: Man

Intermediatire host: Pig

Infective stages: Cysticercus cellulose (Larva)





Humans may develop intestinal infection with adult worms after ingestion of contaminated pork or may develop **cysticercosis** after **ingestion of eggs** (making humans intermediate hosts).

a.1. Humans ingest raw or undercooked pork containing **cysticerci** (larvae).

a.2. After ingestion, **cysts** evaginate, attach to the small intestine by their scolex, and mature into adult worms in about 2 months.

b.3. Adult tapeworms produce **proglottids**, which become **gravid**; they detach from the tapeworm and migrate to the anus.

a.4. Detached **proglottids, eggs,** or both are passed from the definitive host (human) in feces.

b.5. Pigs or humans become infected by ingesting **embryonated eggs or gravid proglottids** (eg, in fecally contaminated food). Autoinfection may occur in humans if **proglottids pass from the intestine to the stomach via reverse peristalsis.**

a.6. After eggs are ingested, they hatch in the intestine and release **oncospheres**, which penetrate the intestinal wall.

b.7. Oncospheres travel through the bloodstream to striated muscles and to the brain, liver, and other organs, where they develop into **cysticerci**. **Cysticercosis** can result.

References

1. Adamson ML, Caira JN. Evolutionary factors influencing the nature of parasite specificity. (Review) *Parasitology*. 1994;109 Suppl:S85–95. [[PubMed](#)]
2. Desnos M, Brochet E, Cristofini P. et al. Polyvisceral echinococcosis with cardiac involvement imaged by two-dimensional echocardiography, computed tomography and nuclear magnetic resonance imaging. *Am J Cardiol*. 1987;59:383. [[PubMed](#)]
3. Flisser A. Taeniassiss and cysticercosis due to *Taenia solium*. (Review) *Progress in Clinical Parasitology*. 1994;4:77–116. [[PubMed](#)]
4. Gemmell MA, Lawson JR, Roberts MG. Control of echinococcosis/hydatidosis. Present state of worldwide progress. *Bull WHO*. 1986;64:333. [[PMC free article](#)] [[PubMed](#)]

5. Ito A, Smyth JD: Adult cestodes. In Soulsby E JL (ed): Immune Responses in Parasitic Infections: Immunology, Immunopathology, and Immunoprophylaxis. Vol. 2. Trematodes and Cestodes. CRC Press, Boca Raton, FL, 1987 .
6. Kammerer WS, Schantz PM: Echinococcal disease. In Maguire JH, Keystone JS (ed): Infectious Disease clinics of North America. Parasitic Diseases 7(3):467, Saunders, Philadelphia, 1993 . [\[PubMed\]](#)
7. McCormick GF. cysticercosis—Review of 230 patients. Bull Clin Neurosci. 1985;50:76. [\[PubMed\]](#)
8. Morris DL, Richards KS: Hydatid Disease: Current Medical and Surgical Management. Oxford, Butterworth-Heinemann LTD., 1992 .
9. Pawlowski ZS: Cestodiasis: taeniasis, cysticercosis, diphyllbothriasis, hymenolepiasis, and others. In Warren KS, Mahmoud AAF (eds): Tropical and Geographical Medicine. 2nd Ed. McGraw-Hill Information Services, New York, 1990 .
10. Schantz PM: Cestode diseases. In Goldsmith R, Heyneman D (ed): Tropical Medicine and Parasitology. Appleton & Lange, East Norwalk, CT, 1989 .
11. Sortelo J, Escobedo F, Penagas P. Albendazole vs praziquantel for therapy of neurocysticercosis. Arch Neurol. 1988;45:532. [\[PubMed\]](#)

The image features a dark blue background with white, stylized circuit board traces in the corners. These traces consist of lines and small circles, resembling a network or data flow diagram. The main text is centered and reads "THANK YOU" in a bold, blue, sans-serif font. Each letter has a thin red outline, giving it a glowing or neon-like appearance.

THANK

YOU